

Lateral Retromalleolar Swelling and Pain

Anuj Taparia, Sunil Kumar, Sonal Saran*

Department of Radiodiagnosis, All India Institute of Medical Sciences, Rishikesh, Uttarakhand, India

SECTION 1 – QUIZ

CASE

A 25-year-old male complained of sudden-onset pain and swelling over the lateral side of the ankle joint in the retromalleolar region. The patient was an athlete and had a history of playing football the previous day. The pain worsened with activity. A dynamic ultrasound scan of the lateral retromalleolar region was performed, and the ultrasound images were obtained in short- and long-axis planes [Figure 1 and Video 1].

WHAT IS YOUR IMPRESSION?

Declaration of patient consent

The authors certify that they have obtained all appropriate patient consent forms. In the form the patient has given his consent for his images and other clinical information to be reported in the journal. The patient understands that his name

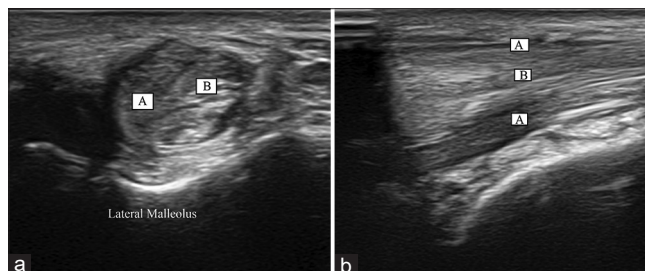


Figure 1: Short-axis (a) and long-axis (b) ultrasound images of the lateral retromalleolar region of the ankle are shown. Identify the structures marked as “A” and “B”

and initial will not be published and due efforts will be made to conceal the identity, but anonymity cannot be guaranteed.

Financial support and sponsorship

Nil.

Conflicts of interest

There are no conflicts of interest.

Received: 04-02-2021 Revised: 09-03-2021 Accepted: 06-04-2021 Available Online: 29-07-2021

Video Available on: www.jmuonline.org

Access this article online

Quick Response Code:



Website:
www.jmuonline.org

DOI:
10.4103/JMU.JMU_30_21

Address for correspondence:

Dr. Sonal Saran,
Department of Radiodiagnosis, All India Institute of Medical Sciences,
Rishikesh, Uttarakhand, India.
E-mail: sonalsaranmalik@gmail.com

This is an open access journal, and articles are distributed under the terms of the Creative Commons Attribution-NonCommercial-ShareAlike 4.0 License, which allows others to remix, tweak, and build upon the work non-commercially, as long as appropriate credit is given and the new creations are licensed under the identical terms.

For reprints contact: WKHLRPMedknow_reprints@wolterskluwer.com

How to cite this article: Taparia A, Kumar S, Saran S. Lateral retromalleolar swelling and pain. J Med Ultrasound 2022;30:162.